

**Intrapartum Management of Vaginal Breech
Delivery (in women who decline or are unsuitable
for Caesarean section) & Management of
complications of Vaginal Breech Delivery**

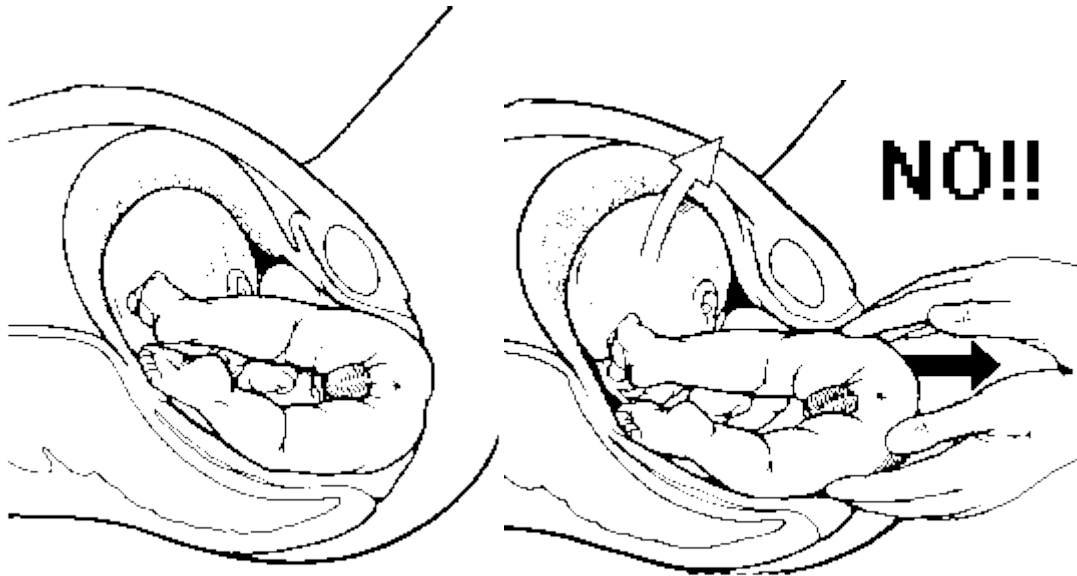
CONTENTS

	Page No.
One page Summary	3
Illustrations of manoeuvres	4-7
Introduction	8
Management of First Stage of Labour	9
Management of Second Stage of Labour	10-12
Manoeuvres for Delivery of aftercoming head	11
Emergency Breech Extraction	12
Entrapment of Fetal Head	13
Emergency Surgical Options	14 -15
Internal Podalic Version	16
Documentation and Debrief	17

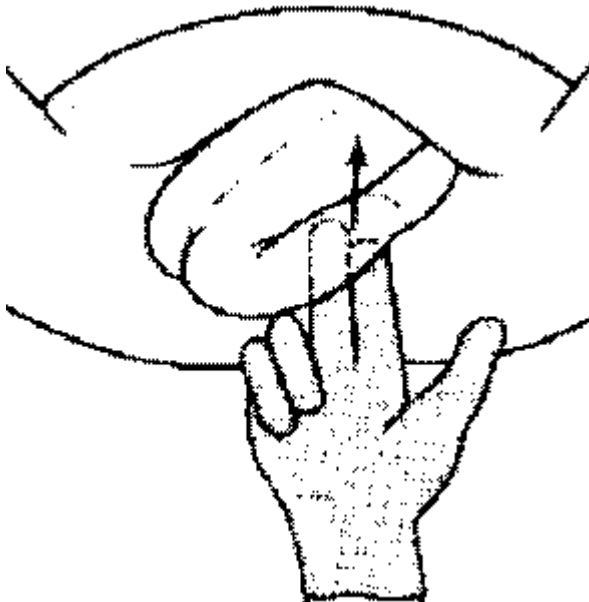
Assisted vaginal breech birth: summary

Assisted vaginal breech birth: summary	
Call for help	Activate emergency bell Request experienced midwife, experienced obstetrician and neonatologist
	Request anaesthetist and theatre team to be on standby
Position of mother	Place mother in lithotomy position unless already on all fours and labour advancing
Evaluate for episiotomy	Evaluate for episiotomy when perineum distended by baby's buttocks
Birth of fetal body and lower limbs	Allow spontaneous birth of the buttocks (hands off)
	Correct buttocks to sacroanterior
	Allow spontaneous birth of legs (hands off) but, if not progressing, assist release of legs by applying pressure to popliteal fossae
	Allow spontaneous birth of body (hands off) until lower scapulae visible
Birth of arms	Allow spontaneous birth of arms (hands off)
	If arms require assistance: Gently hold baby over bony prominences of pelvic bones (not abdomen)
	Keep sacrum/spine anterior
	Rotate trunk (Løvsett's manoeuvre) and sweep fetal arms down using one to two
Birth of head	Allow baby to hang so that shoulders and neck descend over next contraction until nape of neck visible (encourages flexion of head)
	Assist birth of head using Mariceau–Smellie–Veit, Burns–Marshall or forceps placed on to head from <i>underneath</i> body
Documentation	Persons present, Manoeuvres used, Timings of

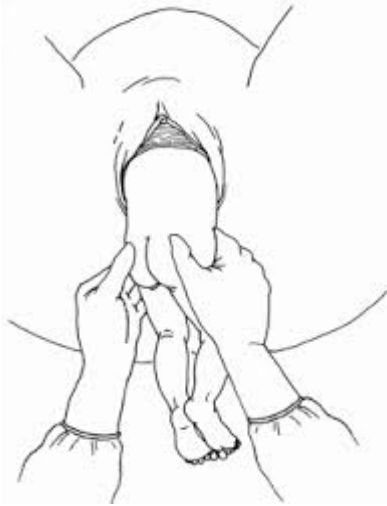1 Allow spontaneous birth of the buttocks



2 Allow spontaneous birth of the legs

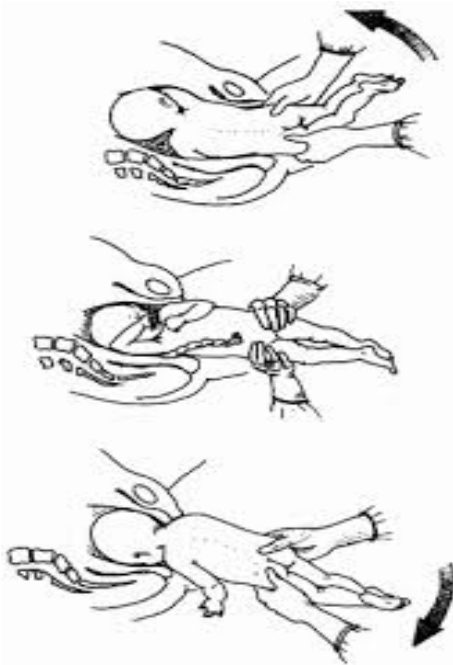


3) Allow the buttocks to spontaneously rotate or gently assist rotation to sacroanterior

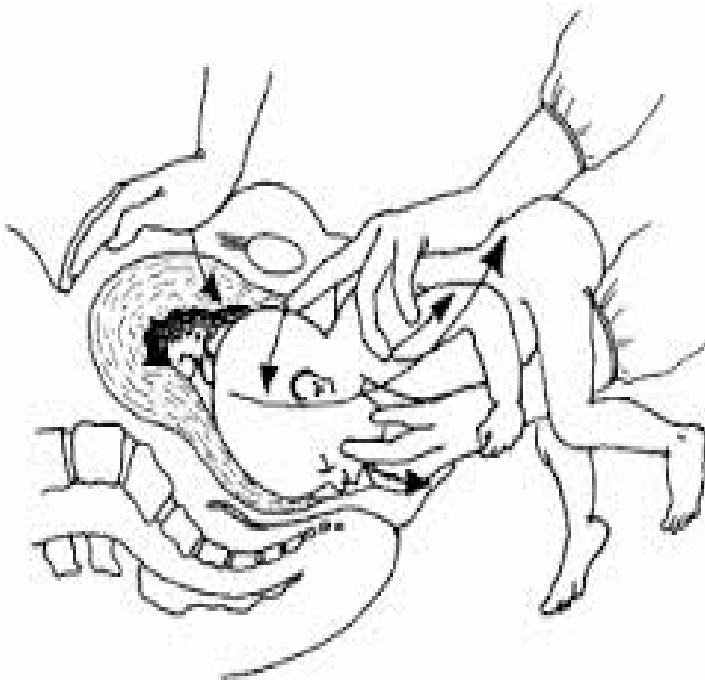


4) Allow spontaneous birth of the body (hands off) until lower scapulae visible

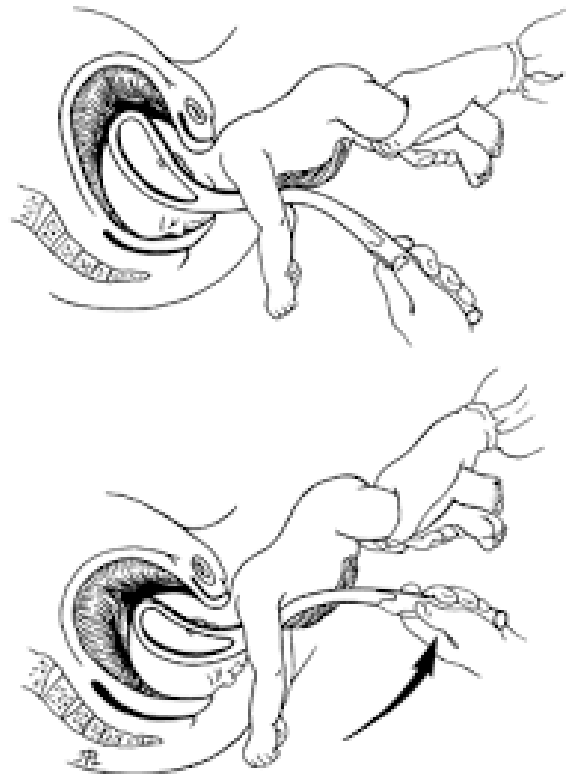
5) Birth of arms- Lovset is not a routine part of a vaginal breech delivery



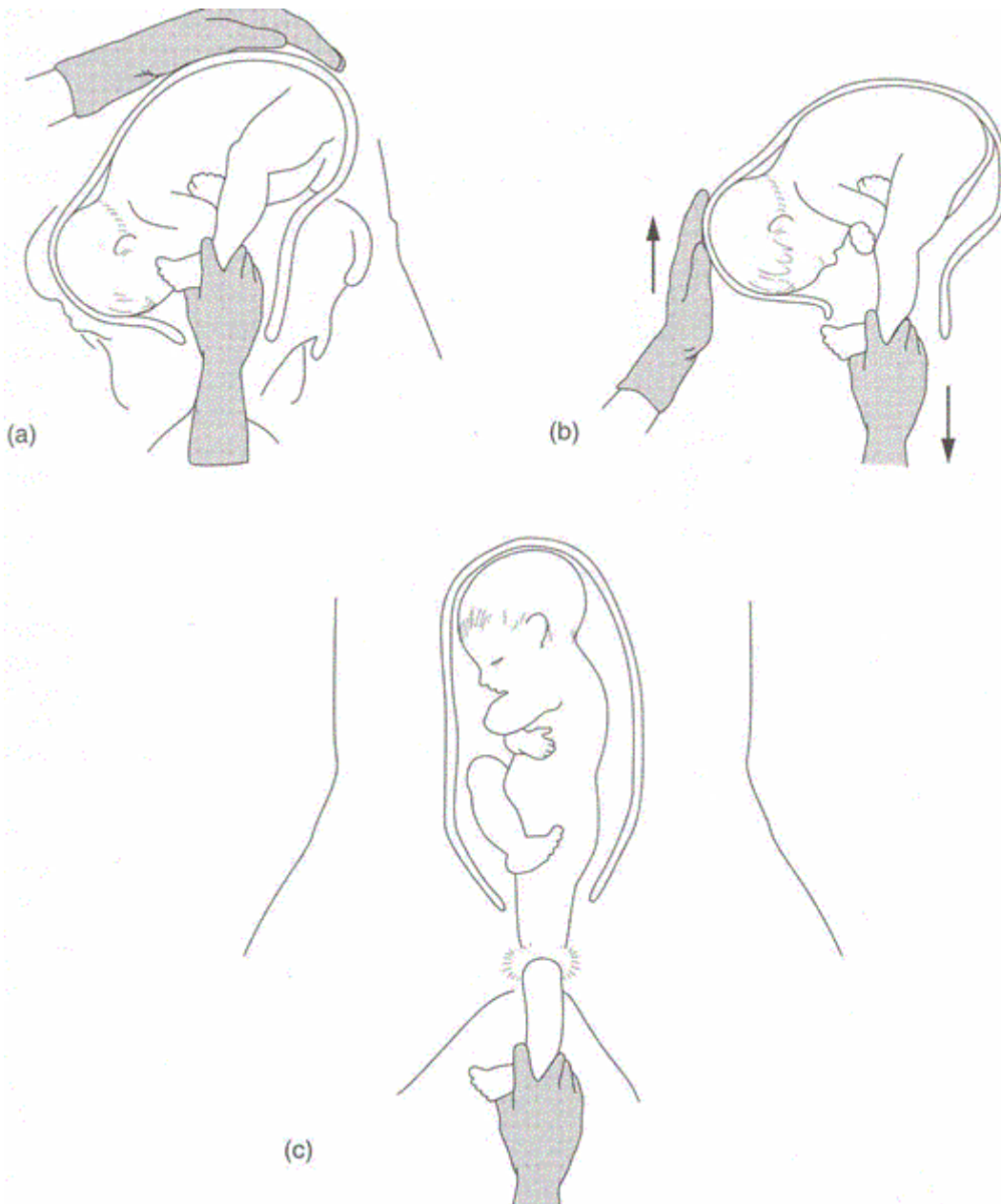
5 Birth of Head



6 Forceps application and delivery of after coming head



7 Breech Extraction (rarely required)



Then continue with manoeuvres for an assisted vaginal breech delivery +/- forceps to aftercoming head.

INTRODUCTION

The incidence of breech presentation is 25% at 28 weeks, 16% at 32 weeks and 3-4% at term. The authors of the term breech trial recommended "the best method of delivering a complete or frank breech singleton **at term** is by planned lower segment caesarean section" based on a 75% reduction in perinatal mortality in the planned CS group. 2 year follow up data did not demonstrate any significant differences in neurodevelopment between the 2 groups. Women who are found to have breech presentation antenatally are offered external cephalic version or delivery at term by elective caesarean section. Some women with a breech presentation at term will make an informed choice to have a trial of vaginal breech delivery. This is best supported when the baby and mother are of normal proportions, the breech presentation is frank (hips flexed, knees extended) or complete (hips and knees flexed, feet not below the fetal buttocks) and the head is not hyperextended, the delivery is carefully planned and a skilled obstetrician is on site.

There is no good evidence to support that caesarean section is the safest mode of delivery for the preterm breech with no other risk factors. Caesarean section for breech presentation at the threshold of viability (22-25+6) w gestation is not routinely recommended.

There are also women who will present in advanced labour with an undiagnosed breech presentation, for which caesarean section may not be an option. It also applies to the delivery of the second twin in breech presentation. Management of complications of vaginal breech delivery is also included in this guidance.

IT IS THEREFORE IMPORTANT THAT CLINICIANS ARE FAMILIAR WITH TECHNIQUES FOR ACHIEVING SUCCESSFUL VAGINAL BREECH DELIVERY

The consultant on call should be notified immediately and a decision made regarding the mode of delivery. The mode of delivery should be individualised based on the gestation, stage of labour, type of breech presentation, station of the breech in the pelvis, fetal wellbeing, the experience of those attending the birth, availability of an operator skilled in vaginal breech delivery and wishes of the labouring woman herself. The RCOG Green Top 20b has stated that selection of appropriate pregnancies and skilled intrapartum care may allow planned vaginal breech birth to be nearly as safe as planned vaginal cephalic birth. It does not follow from this that vaginal delivery is more hazardous than **emergency** caesarean section, particularly when labour is advanced. Ten percent of women in the Term Breech Trial who were randomised to caesarean section delivered vaginally before their section could be carried out.

If a woman chooses not to have a caesarean section or labour is too advanced for caesarean to be undertaken safely, the options are vaginal breech birth or assisted vaginal breech delivery. The former method relies on maternal effort, preferably in an all fours position and the latter on minimal intervention and assistance to facilitate a vaginal breech delivery. The decision as to the most appropriate method would be made at the time depending on factors such as the presence or otherwise of an epidural and the experience of practitioners available on labour ward at the time.

A Management of First Stage of labour in women with breech presentation who decline or are unsuitable for Caesarean section

On admission:

1 Confirm breech presentation by abdominal palpation, portable ultrasound and vaginal examination

Clinical assessment of the fetal size

Assess whether pelvis seems to be adequate.

Ultrasound by a competent practitioner *is useful to:*

Assess the type of breech

Locate the placenta,

Assess size of the fetus (unless AC performed within last 14 days)

Determine the attitude of the fetal head.

Assess Amniotic fluid volume

Assess whether the neck is extended or not

N.B There should be **no** hyperextension of the fetal head. If present: explain to woman what this means. This is a contra-indication to attempting vaginal birth.

Following above assessment:

2

- **Discuss management options** and confirm that the mother still wishes to have a vaginal breech delivery.
 - **Obtain written consent** including options of emergency interventions (Breech extraction and CS) if planned vaginal breech delivery
 - **Inform the consultant obstetrician on call and maternity coordinator**
 - **Inform on-call anaesthetist / neonatal and theatre staff**
 - **Obtain IV access:** large bore cannula (16 or 14) and request **Group and Save**.
 - **Consider pudendal block / perineal infiltration** at delivery
 - **Epidural analgesia** can be helpful however is likely to increase the risk of intervention.
-
- **Membranes should be left intact as long as possible** due to increased risk of cord prolapse with breech presentation

If membranes rupture spontaneously, vaginal examination is required to exclude umbilical cord prolapse.

If membranes are still intact then amniotomy should only be performed for usual indications.

Continuous electronic fetal monitoring should be used with an electrode fixed to the fetal buttock if a good abdominal trace cannot be maintained. Fetal blood sampling is not recommended.

Induction of labour is not usually recommended. Augmentation of slow progress with oxytocin should only be considered if the contraction frequency is low in the presence of epidural analgesia and needs to be discussed with the consultant on call.

B Management of Second Stage of labour with breech presentation

Ideally a consultant obstetrician with experience of vaginal breech delivery should be present for the management of the second stage if time allows.

Basic principles:

- Ensure good maternal effort
 - Do not touch the cord
 - Keep the sacrum anterior
 - Empty bladder
 - Adequate descent of the breech in the passive second stage is a prerequisite
 - Begin active pushing when breech has descended to the pelvic floor and it is visible at the perineum
1. Delay **lithotomy** position until anus is visible over the fourchette (unless breech advancing with good maternal effort on all fours or upright position and only if you are comfortable carrying out any manoeuvres in this position).
 2. **Evaluate for episiotomy** – when perineum distended by baby's buttocks
 3. **Allow spontaneous birth of the buttocks (HANDS OFF)**
 4. **Allow spontaneous birth of legs (HANDS OFF) but if not progressing, and legs extended assist release of legs by applying gentle pressure into the popliteal fossae** to flex the legs at the knee joint.
 5. **Allow the buttocks to spontaneously rotate or gently assist rotation to sacroanterior – HANDLE THE BABY MINIMALLY AND ONLY OVER BONY PROMINENCES OF ILIAC CRESTS TO REDUCE RISK OF TISSUE DAMAGE**

Positioning of back

The baby may be gently grasped by the operator to aid anterior placement of the spine by placing their fingers on the bony fetal pelvis and their thumbs on its sacroiliac region. Avoid holding the baby by the abdomen as this could cause injury to intra-abdominal organs like liver and spleen. Also avoid any downward traction as this could encourage extension of the head and nuchal placement of the upper arms both of which are unfavourable to vaginal breech delivery.

Unnecessary handling or pulling of umbilical cord should be avoided so as to prevent spasm of umbilical vessels.

6. Allow spontaneous birth of the body (hands off) until lower scapulae visible . The fetal body should deliver with maternal effort. Pulling on the infants trunk can startle the baby to raise its arms and therefore should be avoided.

7. Birth of arms

If winging of the scapula is seen, the baby may have become startled with arms extended, or if nuchal arms is diagnosed, the arms may require assistance:

Gently hold baby over bony prominence of pelvic bones (not abdomen)

Keep sacrum / spine anterior to turn the fetal trunk towards the symphysis pubis , , rotate clockwise to the oblique and sweep one fetal arm down (**Lovset's manoeuvre**), then rotate trunk in the opposite direction to the oblique and release the other arm.

N.B Lovset is not a routine part of a vaginal breech delivery

8. Birth of Head

Allow the infant to "hang" using the weight of the baby to encourage flexion of the head until the nape of the neck is visible.

Assist birth of head using Mauriceau- Smellie –Viet, Burns Marshall or forceps placed onto head from underneath the body.

- a) MAURICEAU-SMELLIE-VEIT (MSV) manoeuvre: encourages flexion of the fetal head. Place one hand above the baby with one finger on the fetal occiput and one finger on each of the fetal shoulders. The other hand should be placed below the baby supporting it and 2 fingers should be placed **on** the maxillae (**not in the mouth**). The fetal body is raised upward in an arc completing delivery.

Mauriceau-Smellie-Viet (MSV) manoeuvre for delivery of after coming head

- b) **BURNS-MARSHALL METHOD:** Fetal feet/ankles are grasped and with gentle downwards traction, the trunk is carried up over the mother's abdomen

Application of Forceps to After Coming Head- In some cases forceps may be required to deliver the fetal head.

The head is generally direct OA or no more than 15° left or right.

The assistant should gently lift and support the baby without undue traction.

Its body can be wrapped in a towel to keep it warm

It is important that the fetal back is kept in alignment with the cervical spine and not hyperextended

The forceps are placed from underneath the head. Simulation training is a perfect opportunity to practice this technique. Kiellands, Rhodes and Wrigleys have all been reportedly used for this procedure

Once the first blade is applied any lateral deviation can usually be corrected to DOA.

Once the forceps are applied, check application and lock as next contraction commences

- Gentle downward traction
- Start upward traction once chin on perineum (evaluate for episiotomy if not already done; usual care and angulation)
- Controlled and slow delivery of head
- Transfer baby to waiting neonatal team – if baby requires resuscitation, otherwise perform delayed cord clamping
- Take a cord PH
- Deliver placenta and repair perineum Record Comprehensive note

9 Other procedures

1. Emergency breech extraction (25% RISK BIRTH INJURY)
2. Head entrapment during vaginal breech delivery(more common preterm)
3. Internal Podalic version

Bleep 2222- state obstetric and neonatal emergency – ask for consultant obstetrician and neonatologist to attend and inform anaesthetic and theatre staff.

1. Breech extraction

Breech extraction is most commonly used for delivery of the second twin following internal podalic version (see below).

It may only be performed in a singleton breech if there is sufficient concern regarding fetal well being eg pre-terminal fetal heart rate pattern and it is felt it would be unsafe to proceed with a caesarean section at that time.

Both of your hands are required; one inside and one outside. The uterus should be stabilised with one hand and the second hand is introduced into uterine cavity to grasp both feet if possible but one will do.

Ensure that it is a foot that is grasped and not the hand. If the hand is extracted by mistake, it should be replaced back and the foot/feet should be located and grasped

Ideally during a contraction and with maternal effort, pull down the foot/ feet. It is helpful to assist this process by exerting fundal pressure in a downward direction with the second hand.

Traction should be steady and maintained on the delivered leg(s) until the breech is fixed in the pelvis

Thereafter, action takes the place of contractions and the breech can then be delivered.

FORCEPS APPLICATION TO THE AFTER COMING HEAD may be required following breech extraction

2. Head entrapment during vaginal breech delivery –

Head entrapment during vaginal breech delivery is an obstetric emergency. **(Bleep 2222 and state obstetric and neonatal emergency – ask for consultant obstetrician and neonatologist to attend and inform anaesthetic and theatre staff)**

It is typically associated with preterm vaginal breech delivery when the fetal buttocks and trunk pass through an incompletely dilated cervix. The uterus subsequently contracts and clamps tightly around the fetal head.

Forceps can be used to deliver the after coming head. However, if this fails –

- Re-try Mauriceau-Smillie-Veit (MSV) manoeuvre
- Rotate baby to sacro- transverse
- McRobert's manoeuvre
- Suprapubic pressure
- Tocolysis should be considered (see below)
- Ensure proper documentation
- Cord pH should be obtained
- Debrief the woman postnatally and offer counselling

Tocolysis / Emergency cervico uterine relaxation

Tocolysis with 0.5 mg Terbutaline or GTN (spray of two puffs equivalent to 400 mcg per puff as first line.

General Anaesthesia with a high end tidal concentration of volatile agent eg sevoflurane will often produce useful relaxation of the cervix

GTN increases the risk of PPH.

Emergency Surgical Options- check for cervix

- **Incision of cervix** (Dührssen's incisions) at 10 and 2 o'clock should be considered to avoid cervical neurovascular bundles which is situated at approximately 3 and 9 o'clock and the bladder and bowel which are at 12 and 6 o'clock.

b Symphysiotomy

Technique –

- Adequate analgesia
- Lithotomy position
- Indwelling catheter to bladder
- Incise skin above symphysis with (if available a solid) scalpel. The top of the symphysis is probed with the tip of the scalpel to identify the non bony joint,
- The urethra should be kept displaced from midline by finger in the vagina displacing the catheterised urethra laterally
- The scalpel is advanced at 30 degrees from horizontal and advanced vertically towards the vagina until the sharp tip of scalpel is felt by intravaginal finger. Divide the joint by sawing action
- Once joint is separated, catheter is removed and head should be delivered by forceps
- An episiotomy and traction towards the sacral aspect of the pelvis relieves pressure on the unsupported urethra.
- Postnatal referral to physiotherapy and orthopaedics
- Debrief fully and document discussion.

C Caesarean delivery after replacement of breech (similar to **Zavanelli manoeuvre** for shoulder dystocia) – see shoulder dystocia guideline.

3. Internal podalic version (IPV)-

This may be necessary to deliver:

- a second twin vaginally
- if there is an immediate need to deliver baby.
- Oblique or Transverse lie

Technique-

- One hand is used to stabilise the uterus externally, and the other hand and forearm is introduced into the lower genital tract
- A fetal foot/feet are identified by recognising a heel through intact membranes
- The foot is grasped and pulled gently and continuously lower into the birth canal. The membranes are ruptured as late as possible. The baby is then delivered by using breech delivery manoeuvres as mentioned earlier as an assisted breech or breech extraction with gentle traction on the bony parts of the pelvis, Lovset's manoeuvre to the shoulders if required and a controlled delivery of the head).

If arm is extracted by mistake, it should be gently replaced and foot should be identified again

This procedure is easiest when the transverse lie is with the back superior or posterior. If the back is inferior or if the limbs are not immediately palpable, do not panic, follow the curve of the back and down and round to find the leg. Confirm you have a foot before applying traction. This will minimise the risk of the unwelcome experience of bringing down a fetal hand and arm in the mistaken belief that it is a foot.

If ultrasound is immediately available to an experienced sonographer this may help identify where the limbs are

A few seconds of calm consideration and accurate assessment will almost certainly result in an effective delivery manoeuvre.

Complications of vaginal breech delivery

- **Intrapartum death**
- **Intracranial haemorrhage**
- **Brachial plexus injury**
- **Rupture of the liver, kidney or spleen**
- **Dislocation of the neck, shoulder or hip**
- **Fractured clavicle, humerus or femur**
- **Cord prolapse**

Documentation and Debrief after Vaginal Breech delivery

Careful documentation of the delivery events should be done throughout

Neonatal team should be present at the time of delivery

Paired Cord pH should be obtained following delivery

The woman should have an opportunity for debrief before she is discharged home

Vaginal breech delivery can be very stressful experience for the staff involved as we encounter this situation less frequently, and in most cases, the breech has been undiagnosed until the woman presents in advanced labour or is preterm.

Documentation of complications will inevitably be retrospective and must be clear.

It is important to consider that we work as a team and that all the pressure is not on the obstetrician who may be encountering their first actual vaginal breech delivery, however practice with high fidelity simulation eg PROMPT is essential.

Checklists are recommended for all obstetric emergencies

A scribe needs to be allocated.

Document time of call

Who attended and level of experience

Time persons attended

Manoeuvres attempted and time and by whom.

Drugs (if any) used

Debrief team ideally within an hour of event

Take time to discuss the delivery with the parents and visit the baby if admitted to NNU.

If complicated delivery, contact patients consultant to organise postnatal follow up

Discuss delivery with a mentor of your choice

Originated By: Dr D McLellan

Updated by Dr Clare Willocks

Updated Date: August 2020

Ratified by: Maternity Clinical Effectiveness Group (October 2020)

Review date: October 2023